JNS SPINE

CLINICAL ARTICLE

Return to play in professional football players following traumatic cervical spine injury: expert opinions from the National Football League spine surgeons

Presented at the 2024 AANS/CNS Joint Section on Disorders of the Spine and Peripheral Nerves

***Michael D. White, MD,[1] Andrew M. Hersh, MD,[2] Carly Weber-Levine, MS,[2] Kelly Jiang, MS,[2] A. Daniel Davidar, MBBS,[2] Victoria Bergstein, BA,[2] Vikas N. Vattipally, BS,[2] Scott L. Zuckerman, MD, MPH,[3] Allen K. Sills, MD,[3] Randall W. Porter, MD,[1] and Nicholas Theodore, MD[2]**

[1]Department of Neurosurgery, Barrow Neurological Institute, Phoenix, Arizona; [2]Department of Neurosurgery, Johns Hopkins University School of Medicine, Baltimore, Maryland; and [3]Department of Neurological Surgery, Vanderbilt University Medical Center, Nashville, Tennessee

OBJECTIVE There is a paucity of high-quality return-to-play (RTP) data following treatment of cervical spine injuries in contact sports. In this study, the authors gathered insights from National Football League (NFL) team spine surgeon consultants to highlight current practices in treating cervical spine injuries and report decision-making regarding RTP in professional American football players.

METHODS A cross-sectional, online survey was distributed to all NFL consulting physicians specializing in the management of spine injuries. The survey covered the following five clinical vignettes of cervical spine injuries: 1) radiculopathy, 2) myelopathy, 3) unilateral facet fracture, 4) unilateral facet dislocation, and 5) neck pain with MRI showing a ligamentous STIR signal. Participants were asked about management options and criteria to clear players for RTP using a combination of multiple-choice and open-ended answers.

RESULTS A total of 26 physicians from 21 of 32 (66%) teams responded. Anterior surgery was most commonly recommended for cervical disc herniation causing radiculopathy or myelopathy (73% and 88%, respectively). A rigid cervical orthosis was preferred by 68% of experts for initial management of nondisplaced unilateral facet fracture, but single-level anterior fusion was preferred by 56% for a unilateral facet dislocation. Common criteria to clear players for RTP with cervical disc herniation causing radiculopathy included a normal examination (85%), radiographic fusion postoperatively (58%), and pain-free range of motion (50%). Contraindications for RTP included persistent stenosis (35%), instability (31%), multilevel fusion (27%), and persistent cord signal change (23%). Additional criteria for RTP in players with facet fractures or dislocations included radiographic evidence of fracture healing (32% and 24%, respectively) and normal flexion/extension radiographs (24% and 32%, respectively). Finally, for players with isolated ligamentous STIR signal changes, resolution of MRI findings was required by 36% of responding physicians prior to RTP.

CONCLUSIONS Decision-making regarding RTP after cervical spine injuries in professional football players is complex and influenced by improvement of symptoms, pain-free range of motion, and radiographic evidence of fusion or fracture healing. Respondents preferred anterior cervical discectomy and fusion for disc herniations causing cervical radiculopathy and myelopathy, rigid orthosis for unilateral facet fractures, and surgery for unilateral facet dislocations. The results of this study provide insight into how surgeons serving as consultants to professional football teams may counsel players who sustain cervical spine injuries.

https://thejns.org/doi/abs/10.3171/2024.8.SPINE24421

KEYWORDS football; spine; trauma; return to play; cervical; spinal cord injury

ABBREVIATIONS ACDF = anterior cervical discectomy and fusion; NFL = National Football League; PCF = posterior cervical foraminotomy; PLC = posterior ligamentous complex; RTP = return to play; SCI = spinal cord injury.

SUBMITTED April 2, 2024. **ACCEPTED** August 12, 2024.
INCLUDE WHEN CITING Published online December 20, 2024; DOI: 10.3171/2024.8.SPINE24421.

* M.D.W. and A.M.H. contributed equally to this work.

©AANS 2024, except where prohibited by US copyright law

Brought to you by University of Cincinnati | Unauthenticated | Downloaded 12/21/24 11:16 PM UTC

The high-velocity and high-impact nature of American football places athletes at risk for cervical spine injuries that can range from minor strains causing neck pain to catastrophic spinal cord injury (SCI). Epidemiological studies of injuries sustained by players in the National Football League (NFL) report that approximately 44% of all injuries to the axial skeleton or spine occur in the cervical spine.[1] Additionally, cervical fractures, cervical disc herniations, and traumatic SCI represent three of the top injuries that lead to the most time away from play.[1] Although there is an abundance of literature pertaining to the optimal treatment of cervical pathology in the general population, treatment decisions for football players need to account for additional factors such as lost playing time, effects of surgical intervention on neck mobility and subsequent player performance, risks of reinjury or catastrophic injury when returning to full-contact play, timing of return to play (RTP), and effects on overall career length.

Clearing American football players to return to full-contact play requires complex decision-making, with the potential for significant consequences given the potential high-risk nature of these injuries. Treatment decision-making is at the discretion of players' medical staff and consultants. This study aims to highlight the current practice patterns of professional-team spine surgeons affiliated with NFL clubs in treating various cervical spine injuries and decision-making regarding RTP criteria. These results will provide a better understanding of how these injuries are currently being managed, may educate spine surgeons treating similar injuries among contact sport athletes, and identify areas of incongruity.

Methods

Study Design

The present study was deemed exempt from institutional review board approval. A cross-sectional online survey was created using SurveyMonkey and distributed to 49 NFL spine consultants specializing in the management of spine injuries across all 32 NFL teams. Participation in the survey was voluntary. Demographic information about the participating physician was collected including surgical specialty, level of competitive football players they evaluate clinically and treat, and the number of football-related spinal injuries and surgeries performed.

Survey Vignettes

The survey included five clinical vignettes (Supplementary Survey), with each vignette including a description of the traumatic injury, symptoms, relevant patient imaging, and treatment options. The images were obtained in patients who sustained injuries while playing football but are not from NFL athletes. The first vignette (case 1) described cervical radiculopathy in a hypothetical player experiencing acute-onset right arm pain and hand numbness, without weakness, following a tackle. MRI showed a right C5 nerve root compression from a herniated disc (Fig. 1A). The second vignette (case 2) featured an incomplete SCI at C4–5 with transient weakness and numbness from the neck down. MRI demonstrated diffuse cervical stenosis from a congenitally narrow canal (axial diameter of 9 mm from C2 to C7) with cord edema at C4–5 and no evidence of active cord compression (Fig. 1B). The symptoms improved within 24 hours, but a follow-up visit revealed bilateral hyperreflexia with positive Hoffman's and Babinski's signs. These two cases compared the differences in treatment and RTP considerations for cervical disc herniations causing foraminal stenosis/nerve root compression versus those causing cord compression, incomplete SCI, and myelopathy.

The third vignette (case 3) highlighted a hypothetical player with a unilateral C6 facet fracture from helmet-to-helmet contact. The facet fracture involved less than 40% of the lateral mass and had some extension to the C5–6 facet joint (Fig. 2A). The patient experienced burning paresthesia of the left arm that resolved after 2 days of oral steroids. The fourth vignette (case 4) described a hypothetical player with a unilateral C4–5 facet fracture and dislocation resulting in intense bilateral neck pain radiating to the shoulders with stiffness following a tackle (Fig. 2B). Successful closed reduction of the perched facet was achieved with 40 lbs of traction. Cases 3 and 4 compared differences in management for isolated and nondisplaced unilateral facet fractures versus facet fractures with associated dislocation.

The final vignette (case 5) featured a hypothetical player with immediate sharp neck pain following a blind-side tackle, with MRI showing prevertebral edema and hyperintense signal changes on sagittal STIR sequences consistent with injury of the anterior longitudinal ligament and mild posterior STIR changes in the posterior ligamentous complex (PLC) from C2 to C6 (Fig. 3).

Statistical Analysis

The responses were collected and analyzed using Microsoft Excel. The results were summarized using descriptive statistics including percentages and proportions. Chi-square and Fisher's exact tests were calculated to compare differences in timing of RTP based on respondents' choice of management, with $p < 0.05$ considered statistically significant.

Results

Respondents

A total of 26 spine consultants responded to the survey, representing 21 distinct NFL teams (Table 1). Respondents consisted of 16 (62%) neurosurgeons and 10 (38%) orthopedic surgeons. Most respondents (54%) indicated being in practice for longer than 20 years, with one respondent (4%) practicing less than 10 years. All respondents confirmed caring for professional football players in the last 12 months. Twenty-one (81%) respondents also reported treating football players at the collegiate level, 6 (23%) at the club (recreational) level, and 11 (42%) at the high school and below level. Most participants (81%) saw fewer than 10 football-related spine injuries in the past year, with 5 (19%) seeing greater than 10 injuries. One participant stopped responding after the second vignette and was excluded from subsequent analyses.

Brought to you by University of Cincinnati | Unauthenticated | Downloaded 12/21/24 11:16 PM UTC

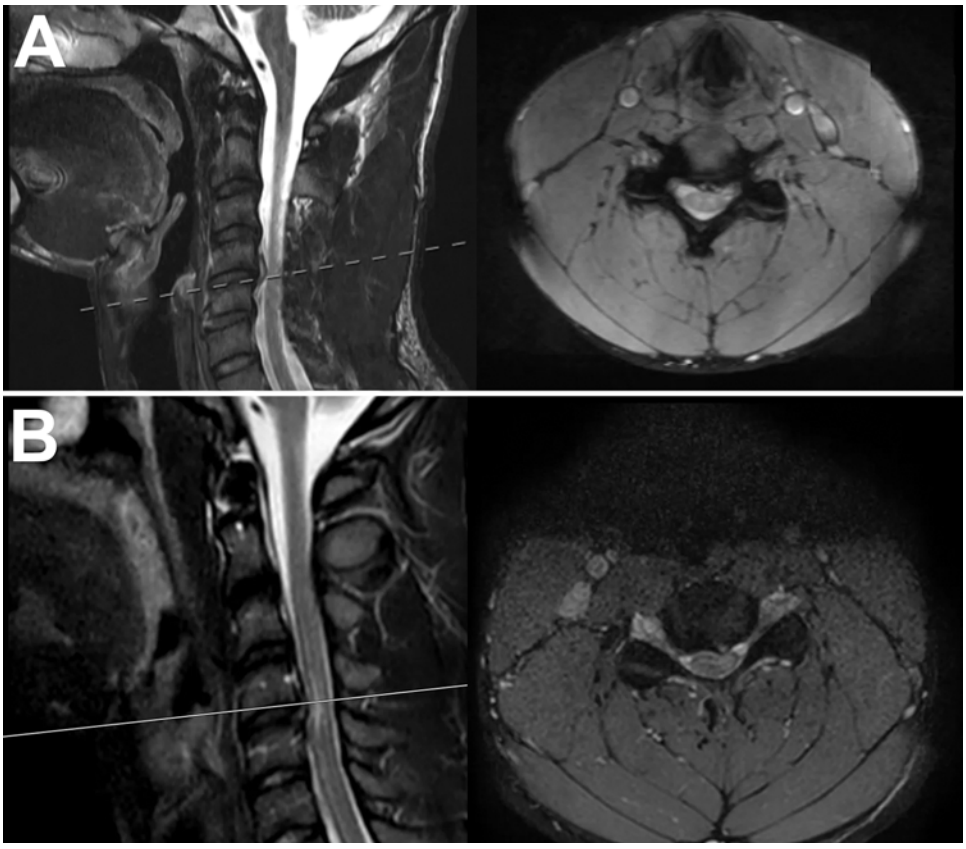

FIG. 1. A: Case 1. Sagittal and axial MR imaging showing a lateral disc herniation causing compression of the right C5 nerve root. **B:** Case 2. Sagittal and axial MR imaging showing broad-based disc herniation at C4–5.

Cases 1 and 2: Cervical Disc Herniation Causing Radiculopathy or Incomplete SCI/Myelopathy

Most respondents favored anterior approaches for players with symptomatic cervical disc herniation, with 19 (73%) and 23 (88%) surgeons favoring anterior cervical discectomy and fusion (ACDF) for radiculopathy and myelopathy/SCI, respectively (Table 2). The majority of respondents did not require bracing after surgery in both cases (62% and 54% for radiculopathy and myelopathy/SCI, respectively). Among respondents who preferred postoperative bracing, there was variability in the timing of bracing. Similarly, most respondents agreed on radiographic follow-up for 12 months (69% and 73% for radiculopathy and myelopathy/SCI, respectively) and resuming light training at 6 weeks (81% and 58% for radiculopathy and myelopathy/SCI, respectively).

For case 1 involving cervical disc herniation and radiculopathy, the consensually recommended time until clearance for return to full professional play was significantly shorter for those recommending posterior cervical foraminotomy (PCF) compared to those recommending ACDF ($p = 0.01$) (subgroup analyses in Supplementary Tables 1–4). Overall, there was significant variability observed with optimal time to resume normal training and full RTP, although 6 months was the most common recommendation for both cases (42% and 38% for the radiculopathy and the myelopathy/SCI cases, respectively). However, 8 (31%) respondents would not allow the player in case 2 to RTP after an incomplete SCI. Conversely, in the case of cervical disc herniation causing radiculopathy, all respondents favored RTP.

The free-response section included additional criteria that respondents use when evaluating a player with cervical disc herniation for RTP. The most commonly cited criteria were normal/improved neurological examination, evidence of solid fusion on postoperative imaging, pain-free and full range of motion, and resolution of abnormal cord signal change if present at the time of initial injury. The most commonly cited contraindications for clearing a player for RTP included persistent symptoms/neurological deficits, continued significant stenosis, persistent abnormal cord signal change on follow-up MRI, and malalignment/instability.

Cases 3 and 4: Unilateral Facet Fracture or Dislocation

The player in case 3 with an isolated and nondisplaced unilateral facet fracture was most commonly treated initially with a rigid cervical orthosis by 17 (68%) respondents. However, cervical orthosis was only recommended by 6 (24%) surgeons as the initial treatment for the player in case 4 with a unilateral facet dislocation. The most commonly chosen treatment for this player was with upfront surgical treatment with ACDF by 56% of surgeons (Table 3). Additionally, 5 (20%) surgeons selected poste-

Brought to you by University of Cincinnati | Unauthenticated | Downloaded 12/21/24 11:16 PM UTC

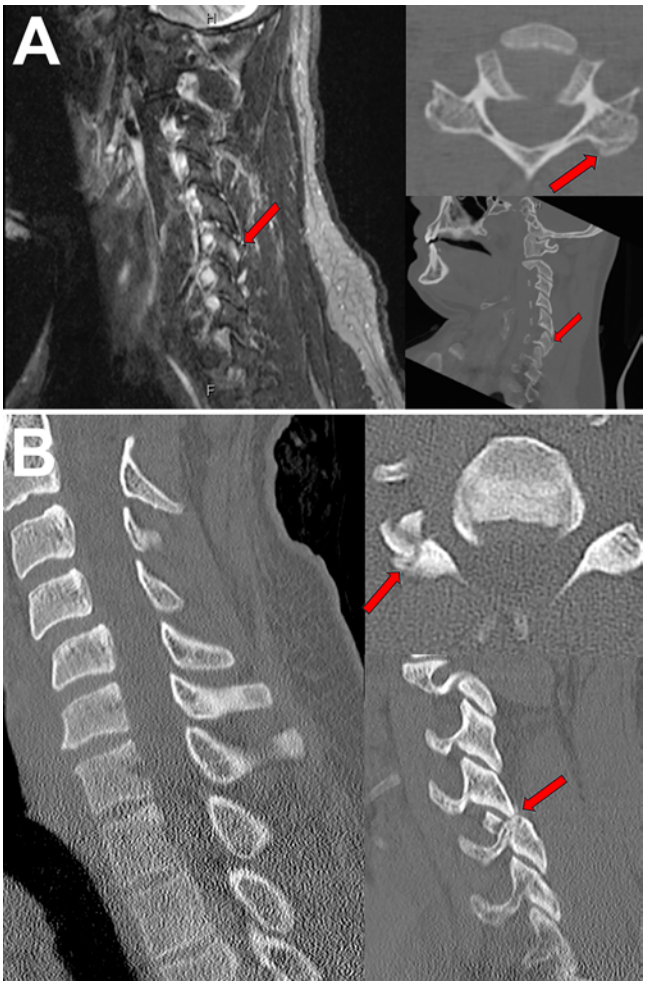

FIG. 2. A: Case 3. Sagittal MR imaging and axial and sagittal CT imaging showing a nondisplaced fracture of the left C6 facet (*arrows*) involving less than 40% of the lateral mass with extension to the C5–6 facet joint. **B:** Case 4. Sagittal and axial CT imaging showing a perched right C4–5 facet (*arrows*). Figure is available in color online only.

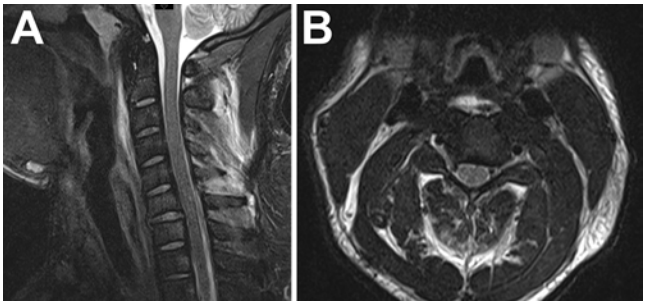

FIG. 3. Case 5. Sagittal (**A**) and axial (**B**) MR imaging showing prevertebral edema and STIR changes consistent with injury of the anterior longitudinal ligament at C2–5, along with mild posterior STIR changes in the PLC of C2–6.

TABLE 1. Characteristics of survey respondents

Characteristic	No. of Respondents (%)
Specialty	
Neurosurgery	16 (62)
Orthopedic surgery	10 (38)
Yrs of practice	
<10	1 (3.8)
11–20	11 (42)
>20	14 (54)
Competitive athletic football players cared for in last yr	
Club	6 (23)
K–12	11 (42)
Collegiate	21 (81)
Professional	26 (100)
Vol of football-related spinal injuries in last yr	
<10	21 (81)
11–25	3 (12)
26–50	2 (7.7)
Vol of spine surgery for football-related injuries in last yr	
0	21 (81)
1–2	3 (12)
3–5	1 (3.8)
>5	1 (3.9)

rior cervical fusion for treatment of the unilateral facet dislocation. There was significant variability observed in the length of bracing by respondents who recommended initial bracing for case 3, with 6 (33%) respondents suggesting 6 weeks, 4 (22%) suggesting 8 weeks, and 8 (44%) suggesting 12 weeks. The two most common intervals selected for radiographic follow-up for the unilateral facet fracture were 6 months (32%) and 12 months (56%). In the case of unilateral facet dislocation, most respondents (80%) recommended continuing radiographic follow-up for 12 months.

Most respondents favored resuming light, noncontact training at either 6 weeks or 3 months, with greater disagreement concerning the time to resume normal training, although most suggested waiting at least 6 months. The recommended timing for players with unilateral facet dislocation to be cleared for full RTP was not significantly different between respondents suggesting initial nonoperative treatment with rigid cervical orthosis and those recommending upfront surgery ($p = 0.64$). All but one respondent recommending initial treatment with cervical orthosis indicated waiting 6–12 months before RTP. Similarly, all but one respondent who recommended initial surgical treatment also suggested waiting 6–12 months before RTP. All surgeons agreed that these players are not contraindicated for eventual RTP.

Additional criteria noted in the decision-making for RTP included normal/improved neurological examination, no radiographic evidence of instability on flexion/

Brought to you by University of Cincinnati | Unauthenticated | Downloaded 12/21/24 11:16 PM UTC

TABLE 2. Respondent choices concerning treatment of a football player who develops cervical radiculopathy (case 1) or myelopathy (case 2)

	No. of Respondents (%; n = 26)	
	Cervical Radiculopathy	Cervical Myelopathy
Op		
ACDF	19 (73)	23 (88)
PCDF	0 (0)	3 (12)
MI-PCF	7 (27)	—
PCD alone	—	0 (0)
Postop bracing		
No bracing	16 (62)	14 (54)
4 wks	6 (23)	4 (15)
6 wks	2 (7.7)	4 (15)
8 wks	1 (3.8)	2 (7.7)
12 wks	1 (3.8)	2 (7.7)
Last radiographic follow-up		
4–8 wks	4 (15)	0 (0)
3 mos	1 (3.8)	3 (12)
6 mos	2 (7.7)	4 (15)
9 mos	1 (3.8)	0 (0)
12 mos	18 (69)	19 (73)
Resume light, noncontact training		
6 wks	21 (81)	15 (58)
3 mos	4 (15)	8 (31)
6 mos	1 (3.8)	3 (12)
9 mos	0 (0)	0 (0)
12 mos	0 (0)	0 (0)
Resume normal training		
6 wks	2 (7.7)	0 (0)
3 mos	8 (31)	6 (23)
6 mos	12 (46)	9 (35)
9 mos	2 (7.7)	2 (7.7)
12 mos	2 (7.7)	9 (35)
RTP		
6 wks	1 (3.8)	1 (3.8)
3 mos	8 (31)	1 (3.8)
6 mos	11 (42)	10 (38)
12 mos	6 (23)	6 (23)
Never	0 (0)	8 (31)
RTP clearance criteria*,†		
Normal/improved neurological exam	22 (85)	23 (88)
Full/pain-free ROM	13 (50)	8 (31)
Fusion on imaging	15 (58)	16 (62)
Maintenance of cervical lordosis	3 (12)	—
Resolution of T2 signal change/ neural compression	—	9 (35)
Contraindications to RTP†		
Persistent deficits/symptoms	15 (58)	15 (58)

CONTINUED IN NEXT COLUMN »

» CONTINUED FROM PREVIOUS COLUMN

TABLE 2. Respondent choices concerning treatment of a football player who develops cervical radiculopathy (case 1) or myelopathy (case 2)

	No. of Respondents (%; n = 26)	
	Cervical Radiculopathy	Cervical Myelopathy
Contraindications to RTP† (*continued*)		
Significant stenosis	9 (35)	8 (31)
Malalignment/instability	8 (31)	5 (19)
Multilevel disease/multilevel fusion	7 (27)	3 (12)
Cord signal change	6 (23)	7 (27)
Pseudarthrosis	4 (15)	4 (15)
History of SCI	—	3 (12)

MI = minimally invasive; PCD = posterior cervical decompression; PCDF = PCD and fusion; ROM = range of motion.
* Respondents who selected "never" for RTP were not included in the analysis.
† Percentages tally above 100% due to respondents writing multiple options. This question was posed as an open-ended response, while the other questions were multiple choice.

extension radiographs, pain-free and full range of motion, radiographic evidence of bony healing of the fracture, and radiographic evidence of fusion for players who underwent cervical fusion. Contraindications to RTP cited in the free-response section included persistent symptoms, abnormal healing of the fracture, kyphosis/malalignment, significant stenosis, instability, or pseudarthrosis for players who underwent cervical fusion.

Case 5: Neck Pain With Anterior Longitudinal Ligament and PLC Injury

There was notable variability among respondents regarding the duration of bracing for the patient in case 5 (Table 4). The most common selection by 11 (44%) respondents was for 6 weeks of bracing, with the second most common selection by 5 (20%) respondents for no bracing at all. Return to full professional play was most commonly recommended after 3 months (36%) or 6 months (40%). One respondent (4.0%) recommended that this player never RTP, citing concern over ligamentous injury and multilevel involvement. Criteria for RTP reported in the free-response section included normal/improved neurological examination, no radiographic evidence of instability on flexion/extension radiographs, pain-free and full range of motion, and resolution of STIR signal on follow-up MRI. Persistent symptoms, evidence of instability, significant stenosis, persistent abnormal MRI signal changes, and multilevel injury were cited in the free-response section as contraindications to clearing this player to RTP.

Discussion

Cervical spine injuries in American professional football players present challenges in decision-making for the optimal management and safe RTP. Our understanding

Brought to you by University of Cincinnati | Unauthenticated | Downloaded 12/21/24 11:16 PM UTC

TABLE 3. Respondent choices concerning treatment of a football player who develops unilateral facet fracture (case 3) or dislocation (case 4)

	No. of Respondents (%; n = 25)	
	Unilat Facet Fracture	Unilat Facet Dislocation
Treatment		
PCF	1 (4)	5 (20)
Single-level ACDF	7 (28)	14 (56)
Rigid cervical orthosis	17 (68)	6 (24)
Bracing length (respondents favoring bracing w/o op)		
4 wks	0 (0)	0 (0)
6 wks	6 (33)	1 (17)
8 wks	4 (22)	3 (50)
12 wks	8 (44)	2 (33)
Bracing length (respondents favoring op)		
No bracing	1 (12)	6 (32)
4 wks	3 (38)	3 (16)
6 wks	3 (38)	4 (21)
8 wks	0 (0)	2 (11)
12 wks	1 (12)	4 (21)
Radiographic follow-up		
4–8 wks	0 (0)	0 (0)
3 mos	2 (8.0)	0 (0)
6 mos	8 (32)	4 (16)
9 mos	1 (4.0)	1 (4.0)
12 mos	14 (56)	20 (80)
Resume light, noncontact training		
6 wks	10 (40)	9 (36)
3 mos	13 (52)	14 (56)
6 mos	1 (4.0)	1 (4.0)
9 mos	0 (0)	1 (4.0)
12 mos	1 (4.0)	0 (0)
Resume normal training		
6 wks	0 (0)	0 (0)
3 mos	6 (24)	7 (28)
6 mos	14 (56)	8 (32)
9 mos	3 (12)	4 (16)
12 mos	2 (8.0)	6 (24)
RTP		
6 wks	1 (4.0)	0 (0)
3 mos	5 (20)	2 (8.0)
6 mos	13 (52)	12 (48)
12 mos	6 (24)	11 (44)
Never	0 (0)	0 (0)
RTP clearance criteria*,†		
Normal/improved neurological exam	21 (84)	19 (76)
Fracture healed on imaging	8 (32)	6 (24)
Normal flexion-extension radiographs (no instability)	6 (24)	8 (32)
Full/pain-free ROM	10 (40)	9 (36)
Fusion on imaging	10 (40)	11 (44)
Contraindications to RTP†		
Persistent deficits/symptoms	10 (40)	12 (48)
Abnormal bony healing/kyphotic deformity	10 (40)	9 (36)
Significant stenosis	4 (16)	5 (20)
Instability	8 (32)	7 (28)
Pseudarthrosis	4 (16)	5 (20)

* Respondents who selected "never" for RTP were not included in the analysis.
† Percentages tally above 100% due to respondents writing multiple options. This question was posed as an open-ended response, while the other questions were multiple choice.

of how operative versus nonoperative treatment for various cervical spine injuries affects the ability of players to safely return to full-contact play has evolved. The prior belief that RTP was contraindicated for players after one-level ACDF, for example, has been largely superseded by a multitude of studies demonstrating RTP to be generally safe with a low risk of subsequent cervical spine–related injury.[2–5] The complexity and wide spectrum of cervical injuries among football players have made establishing standardized protocols for these injuries difficult and impractical. Randomized or multicenter studies to provide clear evidence-based practices are not feasible when studying elite athletes, and our current approach to managing these patients is largely based on small retrospective cohorts and recommendations from experts.[6] Here, we present survey results from 26 consulting football spine surgeons highlighting current practice patterns for management and RTP after traumatic cervical spine injury in professional football players.

Cervical Disc Herniation

Cervical disc herniation is a common pathology among elite athletes and is observed at a higher frequency in professional football players than in the general population.[7,8] Although most cervical disc herniations present with associated symptoms, these typically resolve before complete radiographic resolution, and RTP timing is therefore controversial. Most surgeons would allow RTP when the player is asymptomatic and radiographic images demonstrate resolution of the herniation, while most symptomatic herniations are an absolute contraindication to play.[6,9,10] Isolated cervical radiculopathy is the most common presenting symptom but can also present with bilateral neck pain, myelopathy, or transient quadriplegia.[11] First-line treatment for symptomatic cervical disc herniation is con-

Brought to you by University of Cincinnati | Unauthenticated | Downloaded 12/21/24 11:16 PM UTC

servative therapy for 4–8 weeks, which may include rest, anti-inflammatory medication, immobilization, and therapeutic injections. Other studies have recommended that surgical treatment for acute disc herniations should only be performed in patients with acute neurological deficits, unresolved weakness, or myelopathy.[8]

Cases 1 and 2 presented two hypothetical player-patients with disc herniations: one with persistent radicular symptoms and one with transient weakness and cord signal change. ACDF was the most commonly selected treatment, with 27% of surgeons selecting minimally invasive PCF for players with radicular symptoms. Both procedures have demonstrated near equivalence and good outcomes in the general population,[12] but success in professional athletes is defined by several unique parameters, including time to RTP, career length, neck flexibility, and on-field performance after surgery. For example, Mai et al. reported that 92% of professional athletes undergoing PCF returned to play compared with 70% of those undergoing ACDF.[13] Furthermore, the PCF group returned to play at a rate 35% faster than the ACDF cohort; however, they had significantly higher rates of reoperation (46% vs 6%, respectively).[13] Both ACDF and PCF are viable treatment options, and the decision for one over the other can be influenced by surgeon experience/preference and the goals of treatment. PCF may be an enticing option for players early in the season to expedite their RTP with the understanding that they are at a higher risk for reoperation in the future. Cervical disc arthroplasty was not presented as a treatment choice in the survey, as there have been no published reports of arthroplasty in professional football players. However, there are reports of cases in professional hockey players and collegiate football players.[14–16]

RTP for players with myelopathy or SCI from a cervical disc herniation is complicated by the higher risk of repeat injury and potentially permanent neurological deficits when returning to full-contact play. Resolution of T2 cord signal on follow-up MRI was highlighted by 9 respondents who permit RTP after surgery. Persistent T2 cord signal suggests the presence of neurodegeneration and demyelination within the spinal cord. However, Tempel et al. reported multiple cases of clearing athletes for RTP prior to resolution of T2 cord signal changes, with none of the athletes reporting any episodes of neurapraxia or further injury.[26] They suggested that without ongoing stenosis or instability, the presence of persistent cord signal changes should not prohibit RTP. However, a study of the Cervical Spine Research Society found weak consensus that players with continued T2 cord signal change and a canal diameter less than 13 mm should not be allowed to RTP but can be considered on a case-by-case basis if the canal diameter exceeds 13 mm.[17]

More than half of the respondents indicated that they require follow-up imaging with evidence of solid fusion prior to clearing the player for RTP. Although it is reassuring to have radiographic evidence of solid fusion, evidence is lacking regarding players with asymptomatic pseudarthrosis and whether they can safely return to contact sports. To date, there have not been any reports in the literature of significant implant complications for NFL players after undergoing ACDF and returning to play. The

TABLE 4. Respondent choices concerning treatment of a football player who develops acute neck pain with STIR signal changes (case 5)

	No. of Respondents (%; n = 25)
Bracing length	
No bracing	5 (20)
4 wks	4 (16)
6 wks	11 (44)
8 wks	1 (4.0)
12 wks	4 (16)
Radiographic follow-up	
4–8 wks	2 (8.0)
3 mos	7 (28)
6 mos	8 (32)
9 mos	1 (4.0)
12 mos	7 (28)
Resume light, noncontact training	
6 wks	15 (60)
3 mos	9 (36)
6 mos	1 (4.0)
9 mos	0 (0)
12 mos	0 (0)
Resume normal training	
6 wks	1 (4.0)
3 mos	15 (60)
6 mos	6 (24)
9 mos	1 (4.0)
12 mos	2 (8.0)
RTP	
6 wks	3 (12)
3 mos	9 (36)
6 mos	10 (40)
12 mos	2 (8.0)
Never	1 (4.0)
RTP clearance criteria*,†	
Normal/improved neurological exam	17 (68)
Resolution of MRI findings	9 (36)
Normal flexion-extension radiographs (no instability)	16 (64)
Full/pain-free ROM	10 (40)
Contraindications to RTP†	
Persistent deficits/symptoms	13 (52)
Instability	12 (48)
Significant stenosis	6 (24)
Persistent abnormal imaging	5 (20)
Multilevel injury	2 (8)

* Respondents who selected "never" for RTP were not included in the analysis.
† Percentages tally above 100% due to respondents writing multiple options. This question was posed as an open-ended response, while the other questions were multiple choice.

Brought to you by University of Cincinnati | Unauthenticated | Downloaded 12/21/24 11:16 PM UTC

concern with clearing football players back to full contact with pseudarthrosis at the operative level is the risk of instability. However, biomechanical studies have compared the range of motion in the cervical spine for solidly fused ACDF compared to nonunion models and did not demonstrate any significant differences in range of motion.[18] Our results indicate that radiographic evidence of solid bony fusion is still commonly used as a criterion for RTP; however, evidence is lacking to suggest asymptomatic radiographic pseudarthrosis as a contraindication. Furthermore, the definition of fusion can vary, as some experts may prefer a CT scan while others assess interspinous motion on flexion/extension radiographs.

Facet Fractures and Dislocations

The hypothetical player in case 3 sustained a unilateral facet fracture of C6 without dislocation and resolution of his arm pain after a short course of steroids. A majority (69%) opted for initial conservative management for the hypothetical player with unilateral facet fracture without dislocation. In this case, the fracture involved less than 40% of the facet. Spector et al. demonstrated in the nonathletic population that unilateral fractures > 1 cm or those involving > 40% of the facet were at significantly greater failure risk with nonoperative treatment.[19] Another study by Pehler et al. reported that 85% of patients treated successfully with nonoperative management had fractures < 1 cm in height or < 40% of the facet, with nonoperative management failing in all patients with fractures > 1 cm or > 40% of facet height.[20] Evidence of comminution of the facet fracture has also demonstrated a threefold higher risk of failure with nonoperative management.[20] A trial of conservative treatment with rigid cervical bracing orthosis is a reasonable initial treatment for professional athletes to provide a chance to heal and possibly allow the player to RTP without requiring surgery. However, nonoperative management still has a risk of failure with persistent symptoms or development of instability that may require surgical intervention and extend the player's time away from football.

Case 4 presented a hypothetical player with a unilateral perched facet with neck stiffness that was successfully reduced with closed reduction using 40 lbs of traction. Surgical management was recommended as the initial treatment by most (76%) surgeons for this case, compared to only 32% in the case involving a nondisplaced unilateral facet fracture. Because injuries involving facet dislocation include disruption of the capsule and frequently the surrounding ligamentous structures, nonoperative management has not been shown to be as effective in treating these injuries compared to unilateral nondisplaced facet fractures. Dvorak et al. reported worse long-term pain and disability scores for patients with subaxial cervical facet dislocations treated with nonoperative management compared to surgery, despite this group having more benign fracture patterns.[21] Multiple studies have demonstrated high failure rates with nonoperative treatment in patients with successful closed reduction, most commonly due to failure to maintain adequate reduction/alignment and/or persistent symptoms.[22,23] On the contrary, Hadley et al. reported that 77% of patients who underwent successful closed reduction with external fixation were stable at long-term follow-up.[24] Among these patients, external fixation was most effective in patients with facet fractures at the level of the injury, with external fixation failing in 5 of 7 patients with isolated ligamentous injury without associated bony fracture, suggesting that bony healing may be important for long-term spinal stability.[24]

Given the higher risk of treatment failure with nonoperative management, surgery is often selected for professional football players with facet dislocations to definitively treat the pathology and offer faster RTP.[22,23,25] Nonetheless, the potential outcomes of nonunion from bracing need to be balanced with the risks of surgery. The option of trialing nonoperative management first, particularly in this scenario in which the hypothetical player underwent successful closed reduction with traction, should be discussed with athletes on a case-by-case basis. Moreover, based on the survey results, team spine consultants would generally not clear the player to RTP for 6–12 months regardless of whether they underwent successful nonoperative versus operative treatment.

Ligamentous Injury and STIR Signal

Case 5 presents a hypothetical quarterback with midline neck pain after sustaining a blind-side hit, with MRI demonstrating prevertebral edema and STIR signal throughout the PLC. Survey results demonstrated significant variability in approaches to nonoperative treatment. Bracing was recommended by most respondents, but 20% did not recommend offering bracing at all. Interestingly, 36% of respondents recommended follow-up with repeat MRI showing resolution of the abnormal STIR findings prior to RTP. There is a paucity of literature investigating follow-up MRI for patients with abnormal STIR signal in the PLC and the timing required to see resolution of these radiographic findings.

Limitations

The current results are limited by physician participation, with only NFL consulting surgeons eligible. Although reminders were sent to complete the survey and maximize the response rate, not all club-consulting surgeons participated. There is also a limit to the granularity of data that can be effectively collected, and some of the important nuances in treating these complex injuries are unable to be explicitly defined without further discussion among participants. Although the results do not reflect a formal consensus statement, the survey presents a suitable framework for follow-up Delphi studies. Additionally, the survey-based study design does not allow for the inclusion of all possible cervical injuries, treatment modalities, or clinical questions pertaining to the presented cases. Moreover, respondents may differ in their interpretations of instability and evidence of healing on imaging as criteria for RTP. Finally, the results of this study are the opinions and current practices of physicians in the field based on their own clinical experiences and in the context of the current literature. These results are an indication of how current team surgeons are treating cervical spine injuries and are not definitive treatment or RTP guidelines.

Brought to you by University of Cincinnati | Unauthenticated | Downloaded 12/21/24 11:16 PM UTC

Conclusions

Cervical spine injuries in professional football can significantly impact the neurological functioning of players both on and off the field. Treating this population is unique in that beyond effectively treating the pathology, surgeons must also consider the possibility of RTP, the appropriate clearance criteria for RTP, and the timing for RTP. The results of this study's survey of professional American football team surgeons provide insight into how cervical spine injuries are treated in professional football and considerations of clearing players back to full-contact participation. Clinical criteria commonly cited influencing RTP included improvement of symptoms, pain-free range of motion, and radiographic evidence of fusion or fracture healing. ACDF was the most preferred approach for operative radiculopathy and myelopathy, followed by PCF for radiculopathies. Rigid orthosis was most commonly recommended for unilateral facet fractures, whereas surgery was preferred for unilateral facet dislocations. The survey also highlights that there remains significant variability in treatment patterns and RTP criteria.

References

1. Mall NA, Buchowski J, Zebala L, Brophy RH, Wright RW, Matava MJ. Spine and axial skeleton injuries in the National Football League. *Am J Sports Med*. 2012;40(8):1755-1761.
2. Maroon JC, Bost JW, Petraglia AL, et al. Outcomes after anterior cervical discectomy and fusion in professional athletes. *Neurosurgery*. 2013;73(1):103-112.
3. Hsu WK. Outcomes following nonoperative and operative treatment for cervical disc herniations in National Football League athletes. *Spine (Phila Pa 1976)*. 2011;36(10):800-805.
4. McAnany SJ, Overley S, Andelman S, et al. Return to play in elite contact athletes after anterior cervical discectomy and fusion: a meta-analysis. *Global Spine J*. 2017;7(6):552-559.
5. Kang DG, Anderson JC, Lehman RA Jr. Return to play after cervical disc surgery. *Clin Sports Med*. 2016;35(4):529-543.
6. Huang P, Anissipour A, McGee W, Lemak L. Return-to-play recommendations after cervical, thoracic, and lumbar spine injuries: a comprehensive review. *Sports Health*. 2016;8(1):19-25.
7. Albright JP, Moses JM, Feldick HG, Dolan KD, Burmeister LF. Nonfatal cervical spine injuries in interscholastic football. *JAMA*. 1976;236(11):1243-1245.
8. Zmurko MG, Tannoury TY, Tannoury CA, Anderson DG. Cervical sprains, disc herniations, minor fractures, and other cervical injuries in the athlete. *Clin Sports Med*. 2003;22(3):513-521.
9. Kepler CK, Vaccaro AR. Injuries and abnormalities of the cervical spine and return to play criteria. *Clin Sports Med*. 2012;31(3):499-508.
10. Torg JS, Naranja RJ Jr, Pavlov H, Galinat BJ, Warren R, Stine RA. The relationship of developmental narrowing of the cervical spinal canal to reversible and irreversible injury of the cervical spinal cord in football players. *J Bone Joint Surg Am*. 1996;78(9):1308-1314.
11. Meredith DS, Jones KJ, Barnes R, Rodeo SA, Cammisa FP, Warren RF. Operative and nonoperative treatment of cervical disc herniation in National Football League athletes. *Am J Sports Med*. 2013;41(9):2054-2058.
12. Wirth FP, Dowd GC, Sanders HF, Wirth C. Cervical discectomy. A prospective analysis of three operative techniques. *Surg Neurol*. 2000;53(4):340-348.
13. Mai HT, Chun DS, Schneider AD, Hecht AC, Maroon JC, Hsu WK. The difference in clinical outcomes after anterior cervical fusion, disk replacement, and foraminotomy in professional athletes. *Clin Spine Surg*. 2018;31(1):E80-E84.
14. Brecount H, Goodwin A, Hiltzik DM, Hsu WK. The role of cervical disc arthroplasty in elite athletes. *Curr Rev Musculoskelet Med*. 2023;16(9):432-437.
15. Satalich J, Wyatt P, O'Neill C, Kalluri P, O'Connell R. Cervical disk arthroplasty in a collegiate football player. *J Orthop Case Rep*. 2022;12(9):41-43.
16. Satalich J, Carter S, Fisichella A, Widmeyer J, Kalluri P, Vap A. Return to football after a cervical disk arthroplasty: a case report. *J Orthop Case Rep*. 2022;12(5):19-21.
17. Schroeder GD, Canseco JA, Patel PD, et al. Updated return-to-play recommendations for collision athletes after cervical spine injury: a modified Delphi consensus study with the Cervical Spine Research Society. *Neurosurgery*. 2020;87(4):647-654.
18. Hah RJ, Alluri R, Anderson PA. Biomechanical analysis of an anterior cervical discectomy and fusion pseudarthrosis model revised with machined interfacet allograft spacers. *Global Spine J*. 2020;10(8):973-981.
19. Spector LR, Kim DH, Affonso J, Albert TJ, Hilibrand AS, Vaccaro AR. Use of computed tomography to predict failure of nonoperative treatment of unilateral facet fractures of the cervical spine. *Spine (Phila Pa 1976)*. 2006;31(24):2827-2835.
20. Pehler S, Jones R, Staggers JR, Antonetti J, McGwin G, Theiss SM. Clinical outcomes of cervical facet fractures treated nonoperatively with hard collar or halo immobilization. *Global Spine J*. 2019;9(1):48-54.
21. Dvorak MF, Fisher CG, Aarabi B, et al. Clinical outcomes of 90 isolated unilateral facet fractures, subluxations, and dislocations treated surgically and nonoperatively. *Spine (Phila Pa 1976)*. 2007;32(26):3007-3013.
22. Lifeso RM, Colucci MA. Anterior fusion for rotationally unstable cervical spine fractures. *Spine (Phila Pa 1976)*. 2000;25(16):2028-2034.
23. Beyer CA, Cabanela ME. Unilateral facet dislocations and fracture-dislocations of the cervical spine: a review. *Orthopedics*. 1992;15(3):311-315.
24. Hadley MN, Fitzpatrick BC, Sonntag VK, Browner CM. Facet fracture-dislocation injuries of the cervical spine. *Neurosurgery*. 1992;30(5):661-666.
25. Johnson MG, Fisher CG, Boyd M, Pitzen T, Oxland TR, Dvorak MF. The radiographic failure of single segment anterior cervical plate fixation in traumatic cervical flexion distraction injuries. *Spine (Phila Pa 1976)*. 2004;29(24):2815-2820.
26. Tempel ZJ, Bost JW, Norwig JA, Maroon JC. Significance of T2 hyperintensity on magnetic resonance imaging after cervical cord injury and return to play in professional athletes. *Neurosurgery*. 2015;77(1):23-31.

Disclaimer

The NFL had no role in the decision to pursue or publish this study. The views expressed are solely those of the authors and do not represent those of the NFL.

Disclosures

Dr. Zuckerman reported personal fees from the NFL and Medtronic outside the submitted work. Dr. Sills reported being a salaried employee of the NFL outside the submitted work. Dr. Theodore reported personal fees from Globus Medical outside the submitted work.

Author Contributions

Conception and design: Theodore, White, Sills, Porter. Acquisition of data: Theodore, Hersh, Porter. Analysis and interpretation of data: Theodore, White, Hersh, Weber-Levine.

Brought to you by University of Cincinnati | Unauthenticated | Downloaded 12/21/24 11:16 PM UTC

Drafting the article: White, Hersh, Weber-Levine, Bergstein, Sills. Critically revising the article: Theodore, White, Weber-Levine, Jiang, Davidar, Vattipally, Zuckerman, Sills, Porter. Reviewed submitted version of manuscript: White, Hersh, Jiang, Davidar, Bergstein, Zuckerman, Sills. Approved the final version of the manuscript on behalf of all authors: Theodore. Statistical analysis: Hersh. Administrative/technical/material support: Theodore, Porter. Study supervision: Theodore, Zuckerman, Porter.

Supplemental Information

Online-Only Content

Supplemental material is available with the online version of the article.

Supplementary Tables and Survey. https://thejns.org/doi/suppl/10.3171/2024.8.SPINE24421.

Previous Presentations

Portions of this work were presented as an oral presentation at the 2024 AANS/CNS Joint Section on Disorders of the Spine and Peripheral Nerves Annual Meeting, Las Vegas, NV, February 21–24, 2024.

Correspondence

Nicholas Theodore: Johns Hopkins University School of Medicine, Baltimore, MD. theodore@jhmi.edu.

Brought to you by University of Cincinnati | Unauthenticated | Downloaded 12/21/24 11:16 PM UTC